

# **Riedel's Thyroiditis as a diagnostic dilemma - A case report**

**Dr. Yasir Al Salamh  
Resident General Surgery**

**Dr. Bandar Al Harthi  
Consultant Breast & Endocrine Surgery**

**king Fahad Medical City ,Riyadh**



مدينة الملك فهد الطبية  
King Fahad Medical City



# Case Description – 1. History

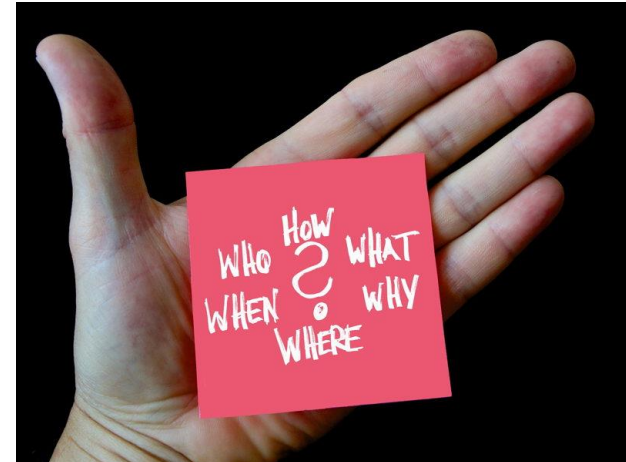

مدينة الملك فهد الطبية  
King Fahad Medical City

A healthy 35 years-old man of Najran district of Saudi Arabia, reported a large mass on front of neck – 1 year.

Associated with, dysphagia, weight loss, not documented fever and symptomatic hypothyroidism and hypocalcaemia.

Smoker-15 years.



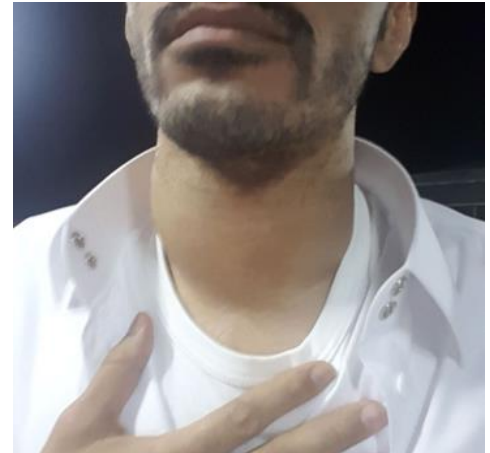

## Case Description- 2. Physical Examination



مدينة الملك فهد الطبية  
King Fahad Medical City

- 18 x 10 cm “woody hard” anterior neck swelling
- Bosselated surface, not moving with deglutition or tongue protrusion.
- Voice change
- Multiple palpable cervical lymph nodes.





## 3. Laboratory Results



مدينة الملك فهد الطبية  
King Fahad Medical City

**Basic Labs  
Normal**

**Low serum  
Calcium**

**TFT  
Hypothyroidism**

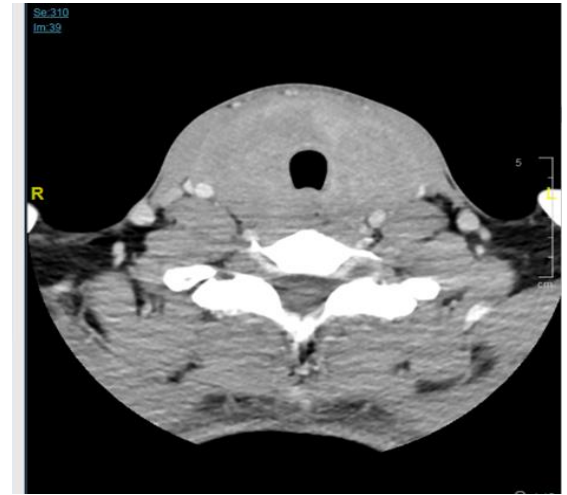
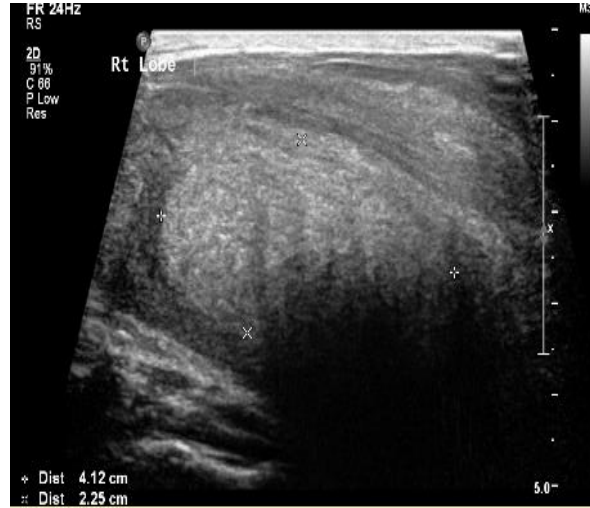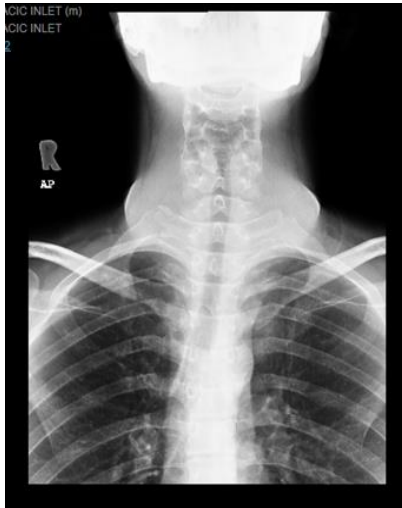**Anti Thyroid  
Antibodies  
Elevated**

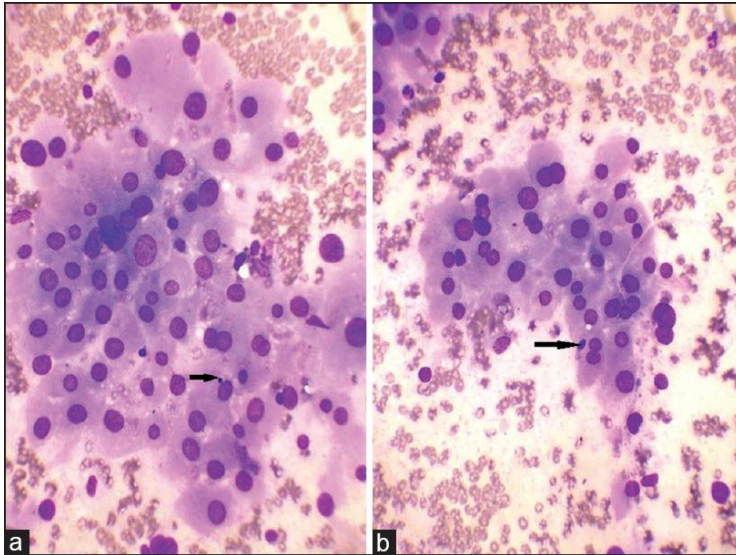


# 4. Imaging



مدينة الملك فهد الطبية  
King Fahad Medical City





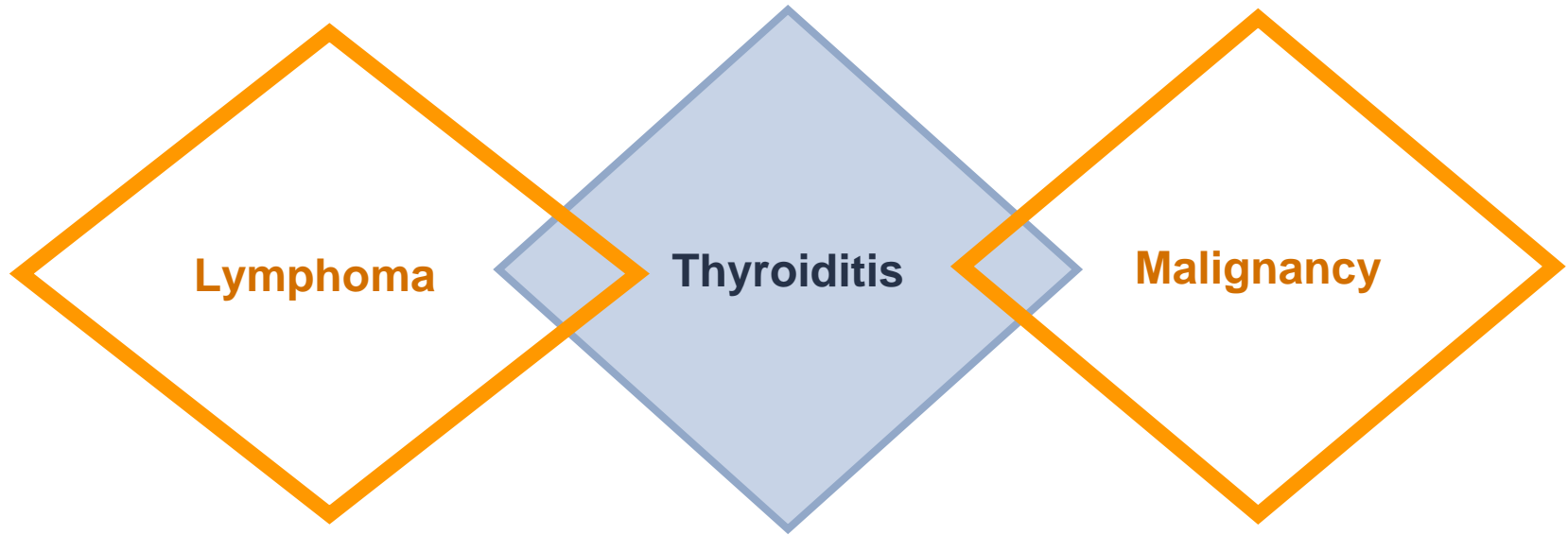
**Done Twice -  
Lymphocytes**



# Deferential Diagnosis



مدينة الملك فهد الطبية  
King Fahad Medical City





# Management



مدينة الملك فهد الطبية  
King Fahad Medical City

- Hematology and Endocrinology services were involved.
- Flow Cytometry – No evidence of Lymphoma





# Management Cont....



مدينة الملك فهد الطبية  
King Fahad Medical City

**“Despite extensive workup in the form of Labs, different imaging modalities and FNAC twice; the thyroid mass was not differentiated from malignancy and other thyroid disorders”**



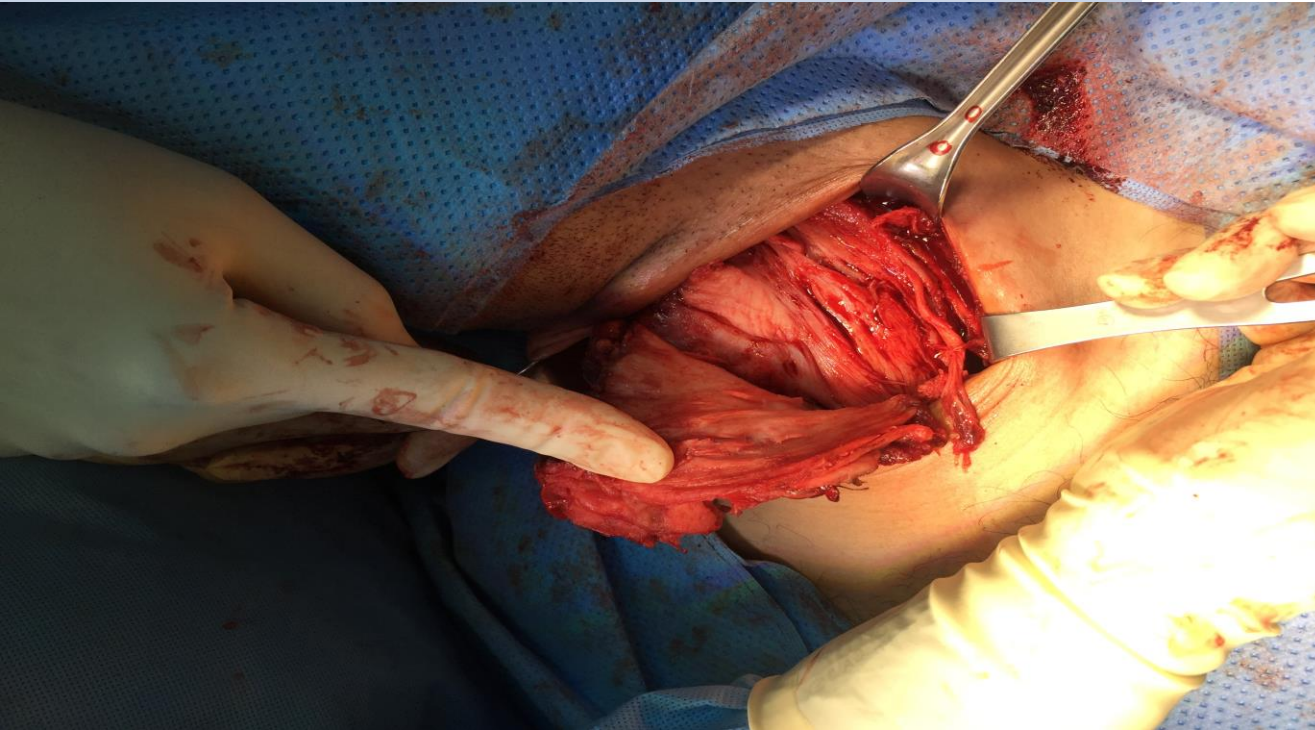# Management Cont....



مدينة الملك فهد الطبية  
King Fahad Medical City

- Planned for a total thyroidectomy
- Partial thyroidectomy and isthmusectomy  
was performed due to intraoperative  
findings.

## Intra operative finding



Whole gland is replaced by fibrous tissue .

Loss of tissue planes .



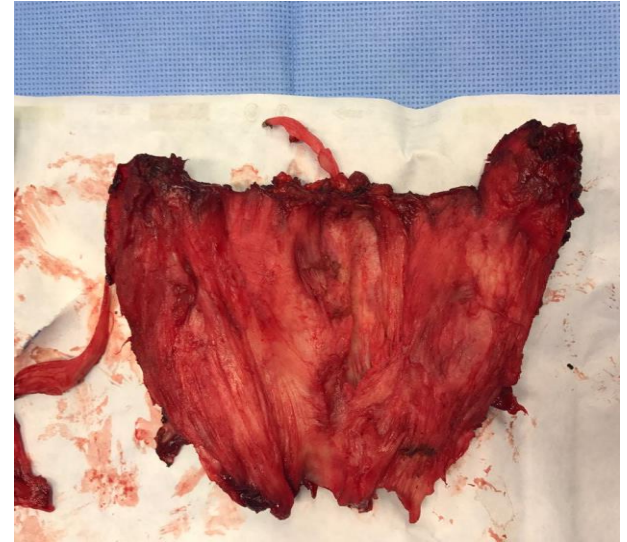# Intra-operative Finding

- Extensive adhesion between thyroid gland and strap muscles
- Huge and woody thyroid tissue with fibrotic appearance

**Frozen section:** Skeletal muscles with lymphocytic infiltrates

**Intraoperative DDX:**

- Riedel's Thyroiditis
- Thyroid Lymphoma
- Strap muscle Sarcoma



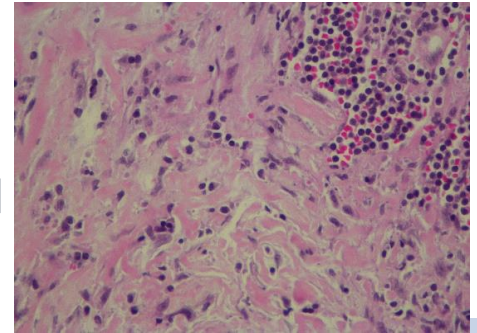
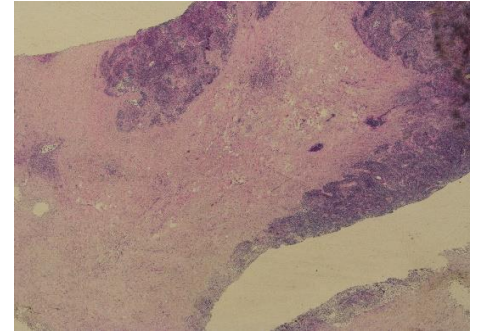


# Histopathology



مدينة الملك فهد الطبية  
King Fahad Medical City

- Fibrosclerotic inflammatory infiltrates consistent with **RIEDELS THYROIDITIS**
- Negative for malignancy
- Entrapped skeletal muscle and vessels
- No thyroid or Parathyroid parenchyma was identified





# Post Surgery Course



مدينة الملك فهد الطبية  
King Fahad Medical City

- No surgical complications with good postoperative recovery.

- He was started on:

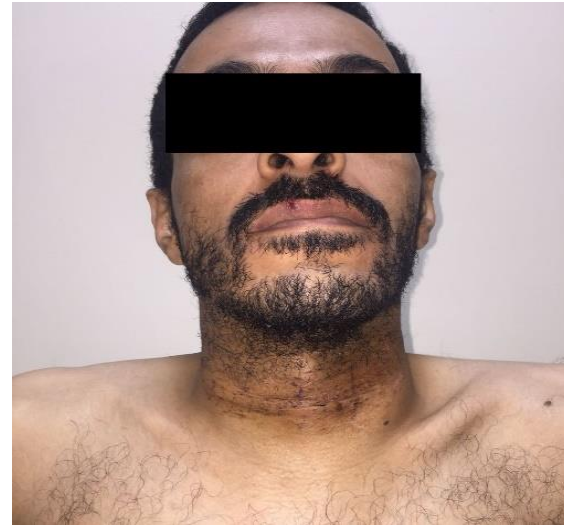**Corticosteroids**

**Tamoxifen**

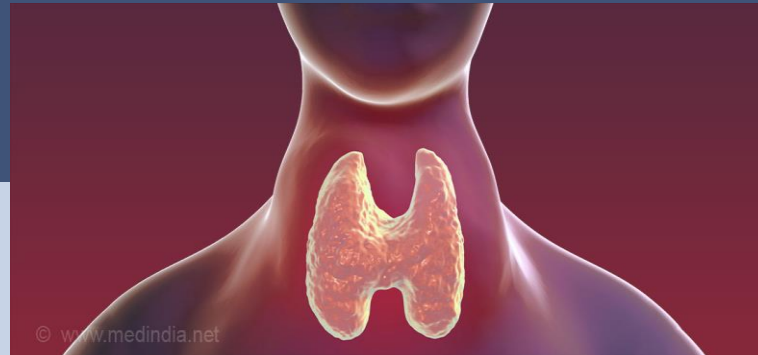
**Levothyroxine**

**Calcium**

- **To which he responded well.**



# RIEDEL'S THYROIDITIS



مدينة الملك فهد الطبية  
King Fahad Medical City



# Background

**Riedel's thyroiditis - Extremely rare form of chronic thyroiditis.**

**Incidence - 1 per 2,000 (0.05%) Thyroidectomies.**

**Fibro-sclerotic process involving thyroid gland and surrounding cervical tissues.**

**Destruction and malfunctioning of thyroid gland and other vital structures.**

Dulani Kottahachchia and Duncan J. Topliss. Immunoglobulin G4-Related Thyroid Diseases. **Eur Thyroid J. 2016** Dec; 5(4): 231–239.

Wang, Chih-Jung, Wu, Ta-Jen, Lee, Chung-Ta, and Huang, Shih-Ming. A misdiagnosed Riedel's thyroiditis successfully treated by thyroidectomy and tamoxifen. **J. Formos. Med. Assoc. 2012**; 111: 719e723



# Background Cont.....



مدينة الملك فهد الطبية  
King Fahad Medical City

**The exact etiology is unknown.**

**Currently most favored view - A localized form of systemic fibrotic process.**

**There has been no report of RT in Middle East.**

**We report a case of RT highlighting a rare presentation of goiter with hypocalcaemia and mimicking thyroid lymphoma**

# Background cont.....



مدينة الملك فهد الطبية  
King Fahad Medical City

- Hard to distinguish - Other thyroid disorders.
- Nonspecific clinical, radiological and FNAB features.
- Can be seen in other diseases that present with involvement

**Hashimoto thyroiditis**

**Lymphoma**

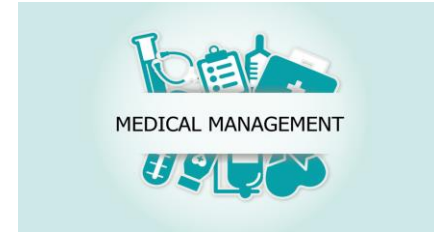**Thyroid carcinoma.**



# Treatment Options

## Medical

- ▷ Corticosteroids
- ▷ Tamoxifen
- ▷ Mycophenolate mofetil
- ▷ Rituximab



Fatourechi MM, Hay ID, McIver B, Sebo TJ, Fatourechi V. Invasive fibrous thyroiditis (Riedel's thyroiditis): the Mayo Clinic Experience 1976-2008. *Thyroid.* 2011;21:765–772

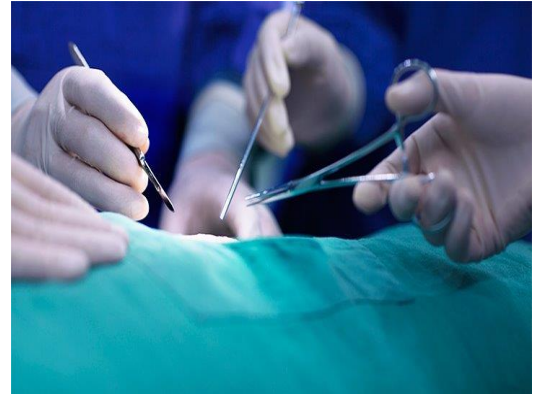Soh SB, Pham A, O'Hehir RE, Cherk M, Topliss DJ. Novel use of rituximab in a case of Riedel's thyroiditis refractory to glucocorticoids and tamoxifen. *J Clin Endocrinol Metab.* 2013 Sep. 98(9):3543-9.

Levy JM, Hasney CP, Friedlander PL, Kandil E, Occhipinti EA, Kahn MJ. Combined mycophenolate mofetil and prednisone therapy in tamoxifen- and prednisone-resistant Reidel's thyroiditis. *Thyroid.* 2010 Jan. 20(1):105-7.

# Treatment Options

## ▀ Limited surgical intervention

- ▷ Obtain tissue diagnosis
- ▷ Rule out malignancy
- ▷ Failure of the medical management
- ▷ Compressive symptoms.



Fatourechi MM, Hay ID, McIver B, Sebo TJ, Fatourechi V. Invasive fibrous thyroiditis (Riedel's thyroiditis): the Mayo Clinic Experience 1976-2008. **Thyroid.** 2011;21:765–772.


Li Y, Nishihara E, Kakudo K. Hashimoto's thyroiditis: old concepts and new insights. *Curr Opin Rheumatol.* 2011 Jan. 23(1):102-7

# Conclusion



مدينة الملك فهد الطبية  
King Fahad Medical City

- Awareness of such clinical entity - speedy diagnosis and avoid complications.
- Medical management should be used to control inflammatory fibrotic process.
- Limited surgical intervention.





مدينة الملك فهد الطبية  
King Fahad Medical City





مدينة الملك فهد الطبية  
King Fahad Medical City



# THANK YOU